By reading this article and writing a practice profile, you can gain a certificate of learning. You have up to a year to send in your practice profile. Guidelines on how to write and submit a profile are featured at the end of this article.

Ear, nose and throat problems in Accident and Emergency page 47-53

Multiple choice questions and submission instructions page 54

Practice profile assessment guide page 55

A reader's practice profile page 28

Ear, nose and throat problems in Accident and Emergency

NS232 Reynolds T (2004) Ear, nose and throat problems in Accident and Emergency. *Nursing Standard*. 18, 26, 47-53. Date of acceptance: September 25 2003.

Aim and intended learning outcomes

Patients with ear, nose and throat (ENT) problems are common attendees at Accident and Emergency (A&E) departments. These patients are sometimes poorly managed due to an (often incorrect) assumption that ENT conditions should be more appropriately dealt with in primary care. However, while the majority can safely wait to see a nurse practitioner or GP, some ENT presentations are acute clinical emergencies. It is often the nurse who assesses the patient initially who detects signs of more serious underlying pathology. The aim of this article is to provide an overview of the common ENT conditions that patients present with in A&E departments. After reading this article you should be able to:

- Understand and describe the simple anatomy of the ear, nose and throat.
- Outline the principles of assessment for patients with ENT problems.
- Describe treatment modalities for patients with ENT problems.
- Identify ENT conditions that constitute an acute clinical emergency.
- Discuss the care and advice that should be given to patients on discharge from A&E departments.

Introduction

There are no reliable figures that demonstrate how many patients with ENT problems attend A&E departments each year. However, nursing staff working in this area will know that patients present with a variety of ENT problems. ENT conditions can often cause patients a great deal of pain and distress (Kilner *et al* 2000). A patient with an acute ENT problem may also have an underlying chronic condition, and he or she might be experiencing a recurrent episode. A minority of ENT problems are life-threatening (Kilner *et al* 2000).

The document *Reforming Emergency Care* (DoH 2001) has laid down stringent targets that A&E departments must meet. The most well recognised of these is the four-hour target, whereby patients must be seen, treated and discharged or admitted within four hours of their arrival in A&E. To achieve this, many trusts have implemented alternative ways of working, such as streaming (DoH 2001). Streaming means that patients will no longer be triaged, but will be placed into an appropriate stream as soon as they enter the A&E department. For the majority of patients, this is a rapid way of ensuring that they get on the most appropriate care pathway in A&E. However, nursing and medical staff should be alert to patients, such as those with ENT problems, who may present with a clinical emergency.

Although the focus of this article is on patients with ENT problems presenting to A&E, the author acknowledges that ENT conditions are also treated in primary care and walk-in-centres. Therefore, the term 'practitioner' is used throughout the article to indicate any professional, nursing or medical, who may encounter such patients.

TIME OUT 1

Before reading on, make a list of the different types of ENT problems that you see in the A&E department where you work. Compare your list with those identified in Box 1.

In brief

Author
Tanya Reynolds RGN, BSc(Hons), MSc, is nurse consultant in A&E, Homerton Hospital, London. Email: tanya.reynolds@homerton.nhs.uk

Summary
Nurses working in A&E departments throughout the UK frequently encounter patients with ear, nose and throat conditions. While the majority of these are straightforward, a small number are serious and even life-threatening. Tanya Reynolds discusses the nursing management of this group of patients and stresses the importance of appropriate assessment, pain management and referral.

Key words
- Accident and emergency nursing
- Ear, nose and throat
- Nursing: care

These key words are based on subject headings from the British Nursing Index. This article has been subject to double-blind review.

Online archive

For related articles visit our online archive at: www.nursing-standard.co.uk and search using the key words above.

Downloaded from RCNi.com by ${individualUser.displayName} on Jul 28, 2016. For personal use only. No other uses without permission.
Copyright © 2016 RCNi Ltd. All rights reserved.

Figure 1. Anatomy of the ear

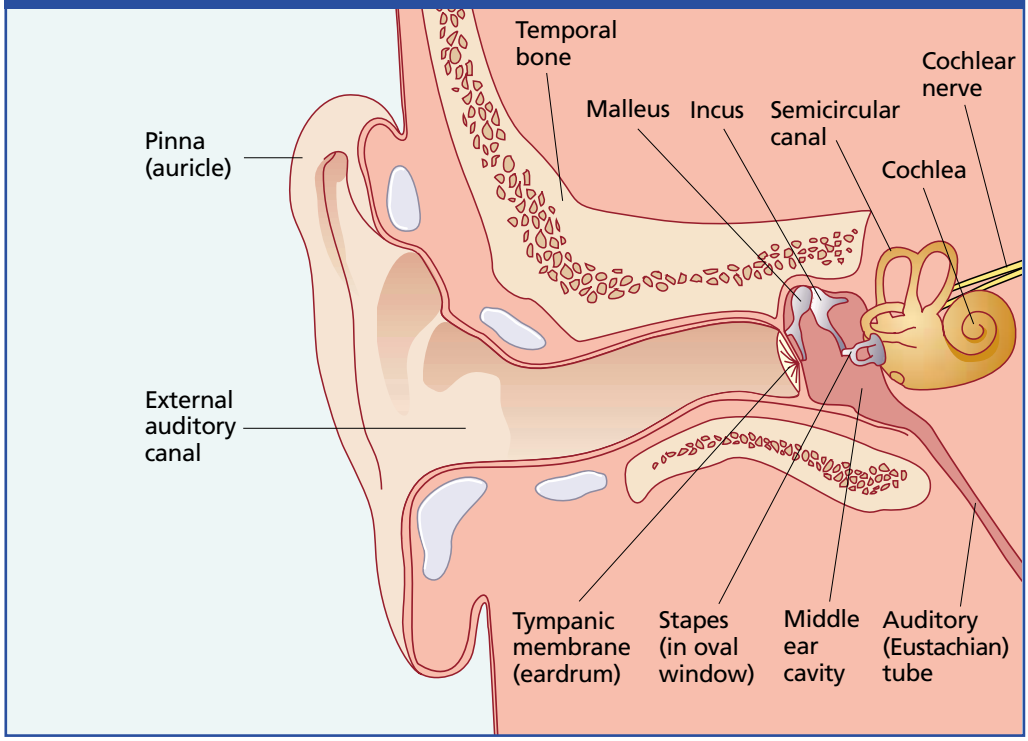

Anatomy of the ear

The ear is divided into three sections: the external, middle and inner ear (Figure 1). The external ear consists of the pinna (or auricle), the external auditory canal (or ear canal), and the tympanic membrane (or eardrum). The ear canal is 25mm long and is lined with cells that secrete cerumen, or ear wax (Bray *et al* 1999).

The air-filled middle ear is separated from the external ear by the tympanic membrane (Bray *et al* 1999), and the inner ear is separated from the middle ear by another membrane, called the oval window. The middle ear contains three ossicles, or bones – malleus, incus and stapes – which connect both of these membranes and transmit sound to the inner ear.

The pharyngotympanic tube, formerly known as the Eustachian tube (Kilner *et al* 2000), connects the middle ear with the nasopharynx and allows the passage of air to equalise pressure on either side of the tympanic membrane (Bray *et al* 1999).

TIME OUT 2

Ask a nurse practitioner or doctor to discuss the principles of ear examination with you, and get him or her to show you how to examine an ear using an auroscope. Write down what you have seen.

Common ear complaints

The majority of patients with an ear problem will present with pain, which may have a variety of causes. It is important to differentiate the more serious conditions, such as acute otitis media or mastoiditis, most of which occur in patients who are systemically unwell rather than as an isolated ear problem. Although most ear problems are unilateral, it is good practice to examine both ears, usually the unaffected first.

Impacted cerumen Ear wax, or cerumen, is produced by glands in the ear canal (Corbridge 1998) and can commonly obstruct the external auditory canal. Impacted wax can be attributed to misguided attempts at cleaning. The ear canal cleans itself by moving desquamated epithelium from the tympanic membrane outward (Beers and Berkow 1999, Corbridge 1998). Using cotton buds to clean the ear canal interrupts the self-cleaning mechanism and promotes accumulation of debris, by pushing it in the opposite direction of the movement of the epithelium.

The patient may complain of itching, pain and a gradual reduction of hearing in the affected ear. Examination of the ear with an auroscope (otoscopy) shows hardened black or dark brown wax in the ear canal. The patient should be advised to take analgesics for pain and to use wax-softening drops, which are widely available from chemists, for two or three weeks (Kilner *et al* 2000). This will soften the wax sufficiently so that it can be removed by syringing at a GP surgery or walk-in-centre. Patients with impacted wax will benefit from appropriate health education and should be advised not to use cotton buds, or any other instruments to clean their ears.

Foreign body Children are the main patient group that present to A&E with a foreign body in their ear, and the object can range from pieces of paper

Box 1. Common ENT presentations in A&E departments

Ear problems
- Impacted wax
- Foreign body
- Otitis externa
- Otitis media
- Mastoiditis
- Furunculosis
- Perforated tympanic membrane
- Trauma

Nose problems
- Epistaxis
- Foreign body
- Trauma

Throat problems
- Viral tonsillitis
- Acute bacterial tonsillitis
- Peritonsillar abscess
- Foreign body
- Airway obstruction

Downloaded from RCNi.com by ${individualUser.displayName} on Jul 28, 2016. For personal use only. No other uses without permission.
Copyright © 2016 RCNi Ltd. All rights reserved.

to small toys. Adults with foreign bodies tend to get the end of a cotton bud stuck, after an attempt at cleaning their ears. Rarely patients may present with an insect stuck in their ear, which can occur in any age group. There might be a delay before presentation with children, as they may be reluctant to tell a parent or carer what has happened until it starts to cause pain (Corbridge 1998).

Removal will be dictated by the type of object *in situ*; hooks can be useful to remove objects as can fine alligator forceps, although care must be taken not to push the object further in (Beers and Berkow 1999, Kilner *et al* 2000). Children should be approached gently to gain their co-operation. Insects in the ear can cause great distress. The instillation of oil will usually drown the insect and promote easy removal by allowing it to flow out (Kilner *et al* 2000). Liquid should be avoided for other objects, such as vegetable matter, as this may cause them to swell (Kilner *et al* 2000).

After two or more unsuccessful attempts at removal in the A&E department the patient should be referred to the ENT department. If a foreign body is successfully removed, the ear should be examined to ensure that no foreign body remains and to exclude trauma caused by the foreign body or its removal.

Acute otitis externa This is a generalised infection of the external auditory canal often caused by injuring the canal while cleaning it (Beers and Berkow 1999). It is often referred to as swimmer's ear (Beers and Berkow 1999, Kilner *et al* 2000) and can be more common in the summer months (Beers and Berkow 1999, Kilner *et al* 2000). It may also be more common in people who use ear equipment at work, for example, audiotypists. Patients with pre-existing skin conditions such as eczema or psoriasis may be predisposed to otitis externa (Corbridge 1998).

During self-cleaning the ear canal traps debris and cerumen which results in an accumulation of water. This can lead to maceration of the ear canal and allow bacteria to enter (Ludman 1997). Patients with otitis externa will experience itching in the ear canal, pain, often discharge and sometimes hearing loss (Beers and Berkow 1999). Applying traction to the pinna can exacerbate this and pressure on the tragus also implies the presence of otitis externa (Beers and Berkow 1999). Examination of the ear canal shows whitish, moist debris often with a foul-smelling discharge.

Treatment usually consists of topical antibiotics, as long as a perforated tympanic membrane has been excluded. For patients with excessive exudate, aural cleaning may need to take place to remove the existing debris from the ear canal (Kilner *et al* 2000). Swabs can be taken if the patient can tolerate it.

Much can be done in the A&E department in the way of offering health education for patients with acute otitis externa, as its onset is largely preventable. Patients should be given appropriate advice about not inserting foreign objects into the ear. However, if this is an occupational hazard, patients should ensure that they are the only person who uses the equipment. Advice on using ear drops should also be given.

Acute otitis media This is a term used for inflammation of the middle ear (O'Neill 1999), a condition that is commonly seen in A&E departments. Up to 30 per cent of these will be children under the age of three years (O'Neill 1999), but this condition also affects older children and adults.

Acute otitis media starts rapidly and presents with systemic and local signs (O'Neill 1999). The symptoms may be associated with an upper respiratory tract infection (Kilner *et al* 2000). The infection spreads to the middle ear via the nasopharyngeal tube and pus collects in the middle ear, leading to pressure on the tympanic membrane (Corbridge 1998). This can cause intense pain and early analgesia should be administered in A&E, as well as an antipyretic, if appropriate (Beers and Berkow 1999). Research suggests that non-steroidal anti-inflammatory drugs (NSAIDs), for example, ibuprofen (or a junior ibuprofen syrup preparation for children) or diclofenac, are more effective in relieving pain than paracetamol (O'Neill 1999). It may be appropriate to consider a multimodal approach to the administration of analgesia and give both an anti-inflammatory drug (for pain) and an anti-pyretic such as paracetamol (for fever) when the patient arrives in A&E, as long as there are no contraindications.

The patient may also be pyrexial, and experience nausea and vomiting, tinnitus and headache (Beers and Berkow 1999, Kilner *et al* 2000). Children may pull at the affected ear. Otoscopy, which can be very painful, will show a bulging tympanic membrane which may spontaneously rupture. Antibiotics are commonly used in the treatment of acute otitis media, and amoxycillin is the drug of choice, unless it is contraindicated (Stafford and Youngs 1999). It can be given for a period of time from five to ten days, depending on the practitioner and local policy. Alternative antibiotics may be given depending on the patient's age and possible causative organisms.

When the patient is discharged, it is important to tell him or her or the carer that the antibiotic course should be completed even if the patient starts to feel better. Female patients who are taking the oral contraceptive pill should be advised of its potential reduced efficacy while taking antibiotics and to seek an additional method of contraception.

TIME OUT 3

Write down the differences between otitis externa and otitis media. Discuss your answer with a colleague.

Mastoiditis This is a complication of acute otitis media and occurs when the infection extends into

Downloaded from RCNi.com by ${individualUser.displayName} on Jul 28, 2016. For personal use only. No other uses without permission.
Copyright © 2016 RCNi Ltd. All rights reserved.

Figure 2. Anatomy of the nose

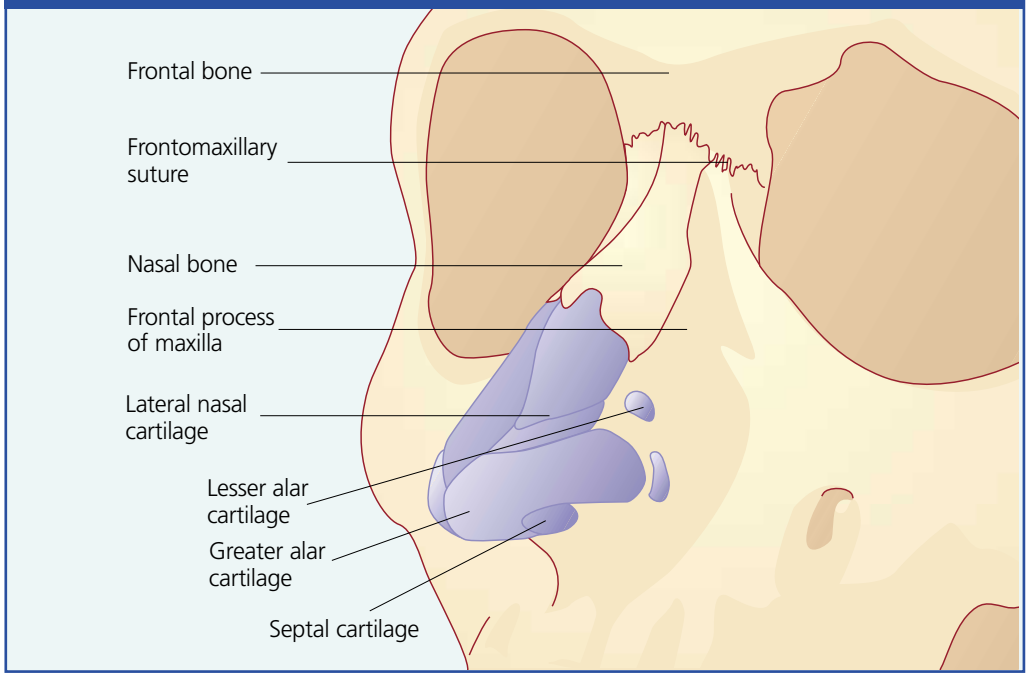

the mastoid antrum (Beers and Berkow 1999). The infection can lead to destruction of the bony portions of the mastoid process. The symptoms will usually become apparent several days after the onset of acute otitis media and the patient will present with redness, swelling and tenderness over the mastoid process (the bony prominence behind the ear) and the pinna will be displaced away from the side of the head (Corbridge 1998). The patient will be in severe pain and there may or may not be a discharge from the ear. Symptoms such as these, which indicate acute mastoiditis, should be treated seriously and the patient should be prioritised as urgent. Patients with this condition require admission for intravenous (IV) antibiotic therapy.

Furunculosis This condition is similar in pathology to acute otitis externa, but tends to be more localised within the external auditory canal (Kilner *et al* 2000) and can present as an abscess or furuncle in the ear canal. The history and presentation are similar to otitis externa except that the pain is more severe (Stafford and Youngs 1999). Generally furuncles are left to drain spontaneously, but the patient will require strong analgesia. Referral to ENT may be appropriate if the furuncle does not resolve.

Perforated tympanic membrane The tympanic membrane (eardrum) can be perforated in different ways: direct trauma, indirect trauma and infection. Direct trauma is the forcible insertion of an object – often a cotton bud – into the ear canal. Indirect trauma, such as a slap over the ear, a diving incident or an explosion, can cause pressure behind the membrane which may result in a perforation (Corbridge 1998). Injuries caused by slaps to the side of the head may be a result of domestic violence (Kilner *et al* 2000) and the patient should be questioned sensitively about this and offered appropriate support, if necessary. A perforation may also occur as a result of a middle ear infection such as otitis media.

The patient with a perforated tympanic membrane will present with a suddenly painful ear, and may complain of bleeding. In addition, there might be some hearing loss (Beers and Berkow 1999). If a perforation occurs as a result of trauma, treatment usually consists of analgesia and ENT follow-up after several days. If it occurs as a result of infection then antibiotics may be required. The patient should be advised to keep the ear clean and not to let any water enter the ear. Eardrops should not be instilled (Corbridge 1998, Kilner *et al* 2000). Generally, a perforated tympanic membrane will heal in a few months, although the patient will need to be referred to the ENT department for assessment and follow-up.

Trauma Trauma to the ear may be accidental or the result of an assault, and can be classified into blunt, such as that sustained during contact sports, and penetrating, which may be caused by contact with a sharp instrument.

Blunt trauma can lead to a sub-perichondrial haematoma, which is a collection of blood between the cartilage and perichondrium (Corbridge 1998, Kilner *et al* 2000). This can lead to avascular necrosis, which in turn can lead to a 'cauliflower' ear – a term used to describe a calcified haematoma (Beers and Berkow 1999). If a patient presents with a new haematoma, treatment is with early aspiration or incision and drainage, followed by a pressure bandage (Corbridge 1998, Stafford and Youngs 1999). Later treatment is by evacuation of the clot.

Penetrating trauma to the pinna can result in full-thickness wounds, which cut across the cartilage. Should this occur, the patient can be referred to an ENT surgeon for surgical repair, which will consist

Downloaded from RCNi.com by ${individualUser.displayName} on Jul 28, 2016. For personal use only. No other uses without permission.
Copyright © 2016 RCNi Ltd. All rights reserved.

of skin sutures that do not penetrate the cartilage. This will ensure correct apposition of the cartilage and result in a good cosmetic appearance. The ear has a good blood supply and usually heals well (Corbridge 1998). A clean, moist dressing should be applied in the interim period.

Anatomy of the nose

The nose consists of bone and cartilage (Figure 2). The skeleton of the nose is attached to the frontal bone and the maxilla (Corbridge 1998) and the rest of the nose is cartilaginous. The nasal septum, which is made of thin sheets of bone and cartilage, separates each nasal cavity. It is a vascular structure and its main functions are to filter, moisten and warm air as it enters the respiratory system, and also to act as a sense organ (Kilner *et al* 2000).

TIME OUT 4

Before reading the next section, outline the common causes of epistaxis and compare your answer with the information provided in Box 2. State the actions you would take to stop epistaxis in a patient who has just arrived at the A&E department.

Common nasal complaints

Epistaxis Epistaxis, or nose bleed, is a common condition and has many causes (Box 2). It is important for the nurse to ascertain the underlying cause, as this may require monitoring and treatment in A&E. The most common bleeding site is the anterior nasal septum also known as Little's area (Kilner *et al* 2000). However, epistaxis can also arise from the posterior nasal cavity.

Initial treatment to stop the bleeding may have already been tried by the patient, although it is important to ensure that he or she has done this correctly. Pinching the nostrils firmly together for 10-20 minutes, just below the nasal bones, is usually successful in arresting the bleeding (Stafford and Youngs 1999). Patients should be advised to keep their head bent forward during the bleed and to cough up rather than swallow any blood (Kilner *et al* 2000) as this may cause nausea and the patient may subsequently vomit the swallowed blood. Application of an ice-pack to the forehead or bridge of the nose can also be helpful (Corbridge 1998).

If the application of direct pressure fails, it is usual to proceed to an alternative method. This may be the insertion of a nasal tampon, such as Epistats™ (if the bleed is from the anterior part of the nose), which applies direct pressure to the bleeding point. Continuous bleeding following pressure may indicate bleeding from the posterior part of the nose and in such cases the nose may need to be cauterised or packed (Kilner *et al* 2000). If epistaxis is spontaneous, or the patient is known to be hypertensive or has a bleeding disorder, then the blood pressure should be checked and clotting studies done. If the patient is hypertensive he or she may need to be given medication in A&E (Kilner *et al* 2000).

Epistaxis is usually a relatively minor complaint but it can turn into a life-threatening problem fairly quickly (Kilner *et al* 2000). Rarely, in the author's clinical experience, some patients, particularly older people, can suffer significant cardiovascular compromise as a result of a nosebleed, which could lead to cardiac arrest, usually pulseless electrical activity. Patients with a compromised circulation should be nursed in a high observation area or resuscitation room and undergo close monitoring of vital signs, coupled with vigorous efforts to arrest the bleeding. Patients who have a cardiac arrest should be resuscitated following the Advanced Life Support (ALS) guidelines (UK Resuscitation Council 2000).

Foreign body This usually occurs in children and is often a delayed presentation. The presence of a foreign body may only have been noticed by the appearance of a purulent discharge from one or both of the child's nostrils (Corbridge 1998). A variety of objects may be inserted into the nostrils. As the perpetrator is generally a child, gentle handling is required as they may be in pain and anxious. This can make an examination difficult or impossible (Epstein *et al* 1997), especially if the child is unsure of what will happen.

If the child is able, he or she should try to blow his or her nose, while the parent occludes the unaffected nostril. If this fails, removal can be encouraged using forceps or specialist ENT instruments. Repeated unsuccessful attempts at removal should be avoided as they can cause further distress and special equipment may be required. If this is the case the child should be referred to the ENT department.

Trauma The nasal bones are the most commonly fractured facial bones (Beers and Berkow 1999, Kilner *et al* 2000). These fractures are caused by direct trauma, which may be accidental or as the result of an assault. There is often a significant degree of soft tissue swelling, which may obscure any deformity and make it difficult to assess the injury initially (Ludman 1997).

If the patient has a nosebleed following an injury, this should be stopped using the measures described above. Any wounds should be cleaned and dressed appropriately and tetanus prophylaxis should be administered as required. If a fracture is suspected and there is a wound over the nasal bone (a compound fracture) the patient may require antibiotic therapy. It is important to ascertain whether or not the patient has suffered a significant head injury. If the history or presenting symptoms indicate this, it should take priority over any nasal injury (Corbridge 1998), although efforts should be made to arrest epistaxis as soon as possible.

Fractures of the nasal bones can lead to the formation of a septal haematoma (Beers and Berkow

Box 2. Common causes of epistaxis

Traumatic
- Direct trauma to the nose
- Excessive picking or blowing

Spontaneous
- Hypertension
- Clotting disorders
- Patients on anticoagulant therapy
- Patients with alcoholism
- Patients with allergies

(Kilner *et al* 2000)

Downloaded from RCNi.com by ${individualUser.displayName} on Jul 28, 2016. For personal use only. No other uses without permission.
Copyright © 2016 RCNi Ltd. All rights reserved.

Figure 3. Anatomy of the throat

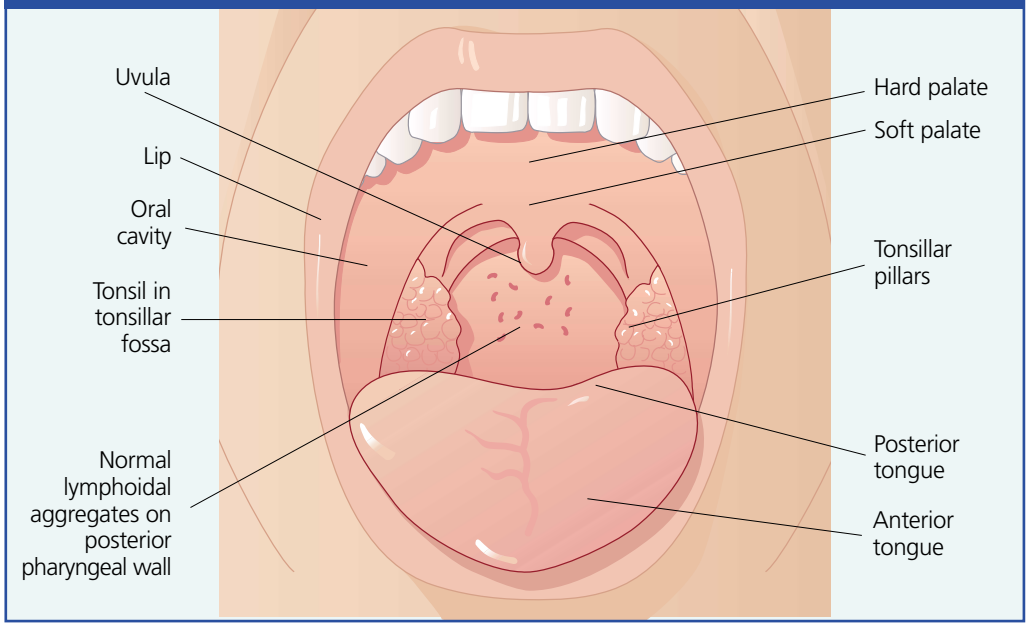

1999), which occurs between the perichondrium and the quadrilateral cartilage. If a septal haematoma is not treated promptly by incision and drainage, it may become infected. This can then lead to the formation of an abscess and necrosis of the nasal cartilage, which may result in a saddle deformity, where the nose becomes flattened over the bridge (Beers and Berkow 1999). A septal haematoma can be easily detected by looking into the nose with a nasal specula: if a haematoma is present it will look like a cherry pushing down. These patients require immediate referral to an ENT specialist.

An isolated nasal fracture with no other injuries does not require an X-ray, as this will not change the patient's management. The patient should be advised to wait seven to ten days for any swelling to subside and if a deformity is suspected he or she should attend an ENT clinic for review and possible reduction of the deformity (Kilner *et al* 2000). The patient should be informed of what to do if the bleeding starts again.

Anatomy of the throat

The throat is a muscular tube consisting of the oropharynx and layrngopharynx (Rogers 1992), which also connects to the nasopharynx. The tonsils are situated in the posterior part of the oropharynx between two folds of muscle and consist of lymphoid tissue (Figure 3). The tongue, which is a mass of striated muscle covered by mucous membrane, is situated on the floor of the oral cavity and extends into the anterior wall of the pharynx (Rogers 1992).

Common throat complaints

Viral tonsillitis This is the most common cause of a sore throat (Corbridge 1998) and is usually associated with other symptoms, such as a blocked nose, cough and cold symptoms and aches and pains. The tonsils will be red but will not have any exudate. The patient should be advised to drink plenty of fluids, take analgesia for pain and gargle with soluble aspirin, which should be swallowed as this will help to ease the symptoms.

Acute bacterial tonsillitis Acute bacterial tonsillitis is common at any age but is more common in children under nine years. It is characterised by sore throat and often referred ear pain (otalgia), dysphagia, fever and malaise (Beers and Berkow 1999). A patient with acute bacterial tonsillitis usually has localised symptoms, and not the generalised symptoms associated with viral tonsillitis.

The tonsils will appear red and swollen, and a whitish-grey discharge will adhere to the tonsils in spots. The patient may find it difficult to open his or her mouth completely and will often have offensive-smelling breath. A swab should be taken but, if the diagnosis is made, it should not be allowed to delay treatment, which is penicillin V 500mg qds (four times a day) for ten days. Fluids, paracetamol and soluble aspirin gargles can be helpful in relieving the symptoms. If the swab indicates *Streptococcus A*, the patient should be followed up by the GP to detect any complications. A serious complication of *Streptococcus A* is acute glomerulonephritis, which can lead to acute renal failure in some patients.

There are several differential diagnoses of acute bacterial tonsillitis, which include glandular fever, diphtheria, scarlet fever and, more recently, sudden acute respiratory syndrome (SARS), although the number of cases has dropped. Patients should be asked if there is any history of recent foreign travel as both SARS and diphtheria can be contracted abroad.

Peritonsillar abscess A peritonsillar abscess, or quinsy, is an abscess on the tonsil and is a complication of acute bacterial tonsillitis where the infection has spread to the tissue lateral to the tonsil,

Downloaded from RCNi.com by ${individualUser.displayName} on Jul 28, 2016. For personal use only. No other uses without permission.
Copyright © 2016 RCNi Ltd. All rights reserved.

causing an abscess to develop (Corbridge 1998). It rarely occurs in children but is more common in young adults (Beers and Berkow 1999) and is usually caused by beta-haemolytic streptococcus.

The patient will complain of a worsening sore throat, with severe pain on swallowing, or inability to swallow (aphagia). This is accompanied by offensive breath and pain on opening the mouth due to spasm of the jaw muscles (trismus). The patient will be systemically unwell, with a fever. Inspection of the back of the throat (which can be difficult due to the trismus) will show a reddened throat, with one tonsil grossly swollen, extending towards the middle of the throat. The uvula may be displaced towards the opposite side (Corbridge 1998).

The patient should be assessed carefully for any signs of respiratory compromise and if present he or she should be nursed in the resuscitation room. Appropriate analgesia and an antipyretic should be prescribed, and the patient urgently referred to an ENT surgeon. The quinsy can then be treated either by incision and drainage or by intravenous antibiotics. Should the patient need to be transferred to another hospital, he or she will need to have a cannula sited and be escorted by an anaesthetist and a nurse.

Airway obstruction Airway obstruction can be attributed to traumatic, infective or reactive causes (Kilner *et al* 2000), and may occur in any age group. Any patient who presents with symptoms suggestive of airway obstruction should be commenced on high flow rate oxygen and monitored in the resuscitation room under the care of an anaesthetist. Signs of airway obstruction are upper airway noises, such as stridor or snoring, difficulty in breathing and drooling (UK Resuscitation Council 2000). In addition, a clear history can be helpful in detecting patients who are at risk of potential airway obstruction.

Traumatic airway obstruction can occur to the mouth and throat from deliberate or accidental trauma. Trauma to the mouth can result in significant bleeding from injuries such as lacerations to the tongue and lips and from avulsed teeth, which could be detrimental to the airway. Trauma to the throat can occur as a result of strangling, hanging or crush injuries to the neck.

Bleeding in the mouth can be stopped by the use of gentle but firm pressure. In children, heavily bleeding wounds can be distressing for patients and parents, and they may require a good deal of reassurance (Kilner *et al* 2000). The majority of wounds to the tongue or lips will not require wound closure, unless they are particularly large or deep, as they heal well with no intervention (Kilner *et al* 2000). Patients with traumatic throat injuries should be treated in the resuscitation room.

Foreign bodies are classed as a traumatic obstruction and can occur in any age group. The majority of these are an uncomfortable irritation rather than a life-threatening event, for example, fish bones. However, any patient with a foreign body in the throat should be observed for signs of obstruction. Some fish and meat bones will show up on X-ray and this can be helpful when treating these patients.

Infective causes of airway obstruction arise from quinsy and epiglottitis. Patients may present with symptoms such as upper airway noises, difficulty in breathing, drooling, and also with the additional presence of systemic signs of illness. Epiglottitis is more common in children and symptoms include fever, dysphagia and drooling. It is essential that the child is kept calm and that repeated attempts to examine the throat are not made, as this can lead to a complete obstruction of the throat, by pushing the epiglottis on to the larynx (Kilner *et al* 2000).

Reactive airway obstruction can occur as a result of an anaphylactic reaction or as a result of exposure to heat or chemicals, for example, following a fire. Swelling occurs to the mouth, tongue and oropharynx, and these patients are at significant risk of developing an obstructed airway and should be monitored appropriately. Patients who have been involved in fires may not have any immediate signs of airway obstruction, and so in the presence of such a history, the nurse should look for singed nasal hairs and eyebrows, carbonaceous sputum in the mouth and blistering to the tongue and lips (Driscoll and Skinner 1999).

TIME OUT 5

The nurse in A&E has a significant role in providing health education and advice for patients and families. Reflect on what you have read and outline what advice you think patients with the following conditions would require:

- A patient with impacted wax in his or her ear
- A patient with a cotton bud tip stuck in his or her ear
- A patient with a perforated tympanic membrane
- A patient with tonsillitis

Conclusion

Ear, nose and throat problems present a challenge to A&E nurses. While the majority of these are straightforward, a small number can be serious and even life-threatening. Assessment should focus on detecting these patients in the light of mounting pressure to meet targets. The majority of patients will be in some degree of pain and nursing staff should ensure that patients are given adequate analgesia. Patients with ENT problems also have important health education needs and these should be addressed in a clear and timely manner

TIME OUT 6

Now that you have finished the article, you might like to write a practice profile. Guidelines to help you are on page 55.

REFERENCES

Beers M, Berkow R (1999) *The Merck Manual of Diagnosis and Therapy*. Seventeenth edition. New Jersey, Merck.

Bray J *et al* (1999) *Lecture Notes on Human Physiology*. Oxford, Blackwell Science.

Corbridge R (1998) *Essential ENT Practice*. London, Arnold.

Department of Health (2001) *Reforming Emergency Care*. London, The Stationery Office.

Driscoll P, Skinner D (1999) (Eds) *ABC of Major Trauma*. London, BMJ.

Epstein O *et al* (1997) *Clinical Examination*. Second edition. London, Mosby.

Kilner T *et al* (2000) Ear, nose and throat emergencies. In Dolan B, Holt L (Eds) *Accident and Emergency: Theory into Practice*. Edinburgh, Baillière Tindall.

Ludman H (1997) *ABC of Otolaryngology*. Fourth edition. London, BMJ.

O'Neill P (1999) Clinical evidence: acute otitis media. *British Medical Journal*. 319, 7213, 833-835.

Rogers A (1992) *Textbook of Anatomy*. Edinburgh, Churchill Livingstone.

Stafford N, Youngs R (1999) *ENT: Colour Guide*. Edinburgh, Churchill Livingstone.

United Kingdom Resuscitation Council (2000) *Advanced Life Support Course*. Fourth edition. London, Resuscitation Council (UK).

FURTHER READING

Jones G (2003) Emergency care of the person with minor injury and minor illness. In Jones G *et al* (2003) *Emergency Nursing Care: Principles and Practice*. London, Greenwich Medical Media.

Acknowledgement

The author wishes to thank Teresa Walsh for her comments during the writing of this article.

Downloaded from RCNi.com by ${individualUser.displayName} on Jul 28, 2016. For personal use only. No other uses without permission.
Copyright © 2016 RCNi Ltd. All rights reserved.